Thomas Jefferson University
Jefferson Digital Commons

Department of Neurology Faculty Papers | Department of Neurology

March 1998

Mitochondrial myopathy with atypical subacute presentation

Oren Cohen
Hadassah University Hospital

Israel Steiner
Hadassah University Hospital

Zohar Argov
Hadassah University Hospital

Avi Ashkenazi
Thomas Jefferson University, avi.ashkenazi@jefferson.edu

Judith Diment
Hadassah University Hospital

See next page for additional authors

Let us know how access to this document benefits you

Follow this and additional works at: http://jdc.jefferson.edu/neurologyfp

Part of the Neurology Commons

Recommended Citation

Cohen, Oren; Steiner, Israel; Argov, Zohar; Ashkenazi, Avi; Diment, Judith; Saada, Ann; and River, Yaron, "Mitochondrial myopathy with atypical subacute presentation" (1998). *Department of Neurology Faculty Papers.* Paper 4.
http://jdc.jefferson.edu/neurologyfp/4

This Article is brought to you for free and open access by the Jefferson Digital Commons. The Jefferson Digital Commons is a service of Thomas Jefferson University's Center for Teaching and Learning (CTL). The Commons is a showcase for Jefferson books and journals, peer-reviewed scholarly publications, unique historical collections from the University archives, and teaching tools. The Jefferson Digital Commons allows researchers and interested readers anywhere in the world to learn about and keep up to date with Jefferson scholarship. This article has been accepted for inclusion in Department of Neurology Faculty Papers by an authorized administrator of the Jefferson Digital Commons. For more information, please contact: JeffersonDigitalCommons@jefferson.edu.

Authors
Oren Cohen, Israel Steiner, Zohar Argov, Avi Ashkenazi, Judith Diment, Ann Saada, and Yaron River

This letter to the editor is available at Jefferson Digital Commons: http://jdc.jefferson.edu/neurologyfp/4

Letter to the Editor

Mitochondrial myopathy with atypical subacute presentation

Mitochondrial myopathies usually have a chronic course of progressive limb weakness, exercise induced myalgia without muscle tenderness, and normal or only mildly raised serum creatine kinase.[1] Acute or subacute presentation or exacerbation of nervous system signs is common in Leber's hereditary optic neuropathy (LHON) and in mitochondrial encephalopathy, lactic acidosis, and stroke-like episodes (MELAS),[1] but has not been reported for muscle in mitochondrial diseases. We describe a patient who presented with rapidly progressive, subacute muscle weakness due to a mitochondrial disorder.

A 38 year old woman presented for the first time with a sudden rapid progression over six weeks of myalgia at rest and muscle weakness. She became bedridden just before admission. On questioning she reported that for about a year she had some muscle pain and a very mild weakness, but continued with all her chores as a mother of six children.

Physical examination disclosed diffuse and pronounced muscle tenderness and moderate to severe proximal limb weakness (3/5 on the MRC scale), with normal strength distally. Tendon reflexes were hypoactive. She had no pyramidal signs and her mental functions, cranial nerves, sensation, and cerebellar functions were intact. The following laboratory tests were normal or negative: blood count, serum electrolytes, liver and renal function tests, arterial blood gases, antinuclear factor, complement concentration, serum protein electrophoresis, and thyroid hormone and cortisol concentrations. However, her erythrocyte sedimentation rate was accelerated (65/115), and serum creatine kinase concentrations were slightly raised (146 units, normal <110 units). Serum lactate concentration was high at rest (7.8 mM/l, normal <2.0 mM/l), and further increased during ischaemic exercise.

Electrodiagnostic evaluation disclosed a sensory polyneuropathy (conduction velocity of 32.9 m/s in the right sural nerve), with reduced recruitment, and some large amplitude, polyphasic units on EMG of the right quadriceps, tibialis anterior, and gastrocnemius muscles. Muscle biopsy disclosed many ragged-red fibres but no inflammation or myonecrosis. Electron microscopy confirmed the presence of abnormal mitochondria, some of which contained paracrystalline inclusions (figure). NADH cytochrome c oxydoreductase, ubiquinol/cytochrome c reductase and cytochrome c oxidase activities in muscle homogenate were 59 nmol/min/mg (10% of control values), 1.02 µmol/min/mg (40% of control values), and 1.14 nmol/min/mg.

(20% of control values), respectively. DNA analysis for the common mutations of MERRF (tRNALys position 8344), MELAS (tRNALeu position 3243), and Kearns-Sayre syndrome (large deletions) was negative. Treatment with vitamin E (800 mg/day), vitamin C (2 g/day), ubiquinone (120 mg/day), and carnitine (330 mg/day) was initiated. A dramatic improvement of the patient's muscle strength ensued within a few weeks. Three months later only mild weakness without tenderness could be detected and the patient was stable, under treatment, throughout a year of follow up. She resumed her

J Neurol Neurosurg Psychiatry 1998;**64:**410-411 (March)

Copyright © 1998 by the BMJ Publishing Group Ltd.

normal activities. Further evaluation, a year after initiation of therapy, disclosed only very mild proximal limb weakness. A repeated muscle biopsy again showed numerous ragged-red fibres and reduced activity of the respiratory chain enzymes NADH ferricyanide reductase, NADH-cytochrome c oxireductase, cytochrome c oxidase (complex IV), NADH-ubiquinone reductase (complex I), and ubiquinol-cytochrome c reductase (complex III).

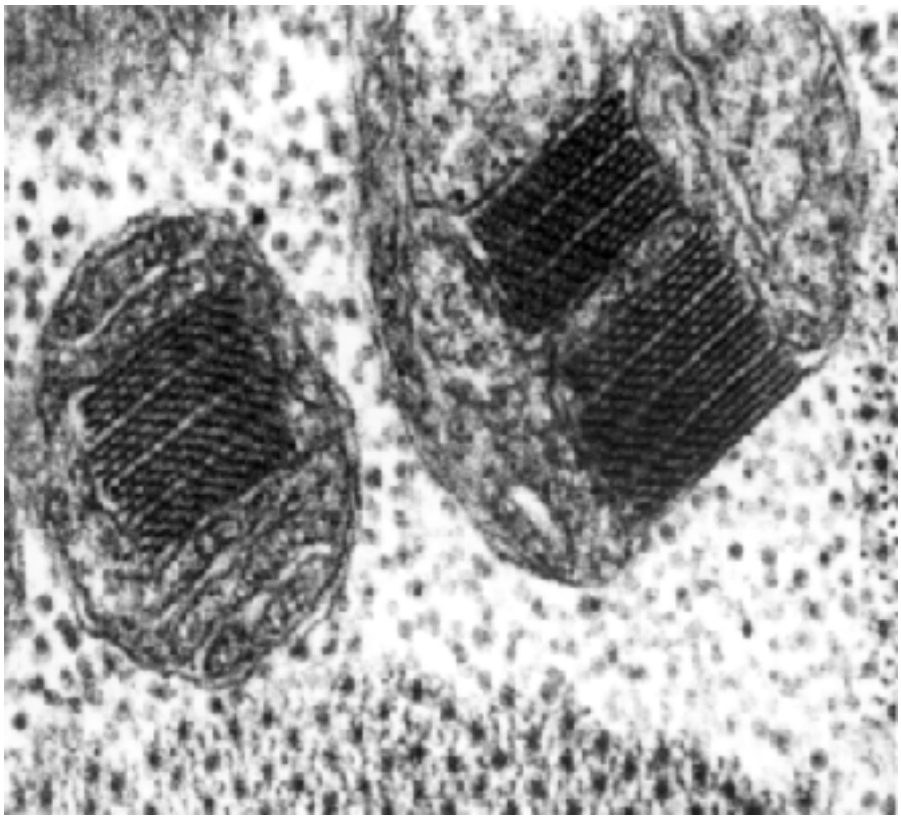

Mitochondria with typical paracrystalline inclusions.

The patient described here presented with subacute onset, at adulthood, of myalgia and muscle tenderness at rest, proximal weakness, raised creatine kinase, and accelerated erythrocyte sedimentation rate. These features strongly suggested an inflammatory myopathy, but serum lactate abnormality and muscle biopsy established the unexpected diagnosis of a mitochondrial disease. This patient had two uncommon features for primarily mitochondrial myopathies: the subacute mode of presentation and the dramatic and rapid response to cofactor therapy. We have seen another two patients with a similar subacute presentation of mitochondrial myopathy in whom a less extensive investigation was done.

J Neurol Neurosurg Psychiatry 1998;**64:**410-411 (March)

Copyright © 1998 by the BMJ Publishing Group Ltd.

Few ragged-red fibres and mitochondrial morphological changes have been reported in inflammatory myopathies, including polymyositis, dermatomyositis, and inclusion body myositis,[2 3] and mitochondrial DNA abnormalities were recently described in patients with inclusion body myositis.[3] However, these changes are considered secondary and their pathophysiological role in the disease is unclear. The absence of any histological features of inflammation, necrosis, or rimmed vacuoles, the abnormalities of serum lactate concentrations, and the respiratory chain enzymatic abnormalities strongly suggest that our patient had a primary mitochondrial disorder.

Mitochondrial muscle disease usually follows a slowly progressive course attributed to dysfunction of oxidative metabolism and mitochondrial energy production.[1] The subacute presentation, accelerated course, myalgia, and raised erythrocyte sedimentation rate and creatine kinase concentrations are therefore very atypical for this disorder. What might be the mechanism of such an unusual course of a mitochondrial muscle disease? One explanation is that muscle destruction can induce a secondary immune process due to the continuous presentation of cytoplasmic or nuclear antigens to the immune system. Such a mechanism may account for the few reported cases[2 3] of pathological features of inflammatory myopathy with ragged-red fibres and mitochondrial DNA abnormalities. Nevertheless, muscle biopsies from our patients disclosed no inflammation, a finding that could have supported this theory.

An alternative possibility is that an accelerated necrotic process and the cell destruction in the muscle can result from an acute energy crisis. This is supported by the reported cases of myoglobinuria in mitochondrial disorders.[4] A similar but slower mechanism may explain the relatively rapid presentation in our patient, as well as the subacute mode of presentation of other mitochondrial disorders such as MELAS and LHON.

Although clinical improvement was previously reported in mitochondrial disorders after cofactor therapy, multiple complex deficiencies are associated with multisystem failure and early death.[5] A possible explanation for the pronounced improvement after treatment in our patient might be the threshold effect and the heteroplasmy phenomenon.[1] Theoretically, a critical subgroup of mitochondria with only a mild enzymatic defect may regain function after treatment with electron acceptors, the threshold for function is obtained and culminates in clinical improvement.

The atypical presentation in our patient broadens the range of mitochondrial muscle disorders to include a polymyositis-like syndrome. It is recommended that blood lactate concentration screening would be performed in all patients with subacute onset of muscle weakness.

OREN COHEN, ISRAEL STEINER, ZOHAR ARGOV, AVI ASHKENAZI
Department of Neurology

JUDITH DIMENT
Department of Pathology, Hadassah University Hospital, Jerusalem, Israel

J Neurol Neurosurg Psychiatry 1998;**64:**410-411 (March)

Copyright © 1998 by the BMJ Publishing Group Ltd.

ANN SAADA
The Metabolic Diseases Unit, Shaare Zedek Medical Centre, Jerusalem, Israel

YARON RIVER
Department of Neurology, Hadassah University Hospital, Jerusalem, Israel

Correspondence to: Dr Oren Cohen, Department of Neurology, Hadassah University Hospital, PO Box 12000, Jerusalem 91120, Israel. Telephone 00972 2 6776941; fax 00972 2 6437782.

References

1. DiMauro S, Moraes CT. Mitochondrial encephalomyopathies. *Arch Neurol* 1993;**50**:1197-1208.

2. Rifai Z, Welle S, Kamp C, *et al*. Ragged red fibers in normal aging and inflammatory myopathy. *Ann Neurol* 1995;**37**:24-29.

3. Horvath R, Fu K, Genge A, *et al*. Mitochondrial DNA abnormalities and the pathogenesis of sporadic inclusion body myositis. *Neurology* 1996;**46**(suppl):117.

4. Ohno K, Tanaka M, Sashashi K, *et al*. Mitochondrial DNA deletions and in inherited recurrent myoglobinuria. *Ann Neurol* 1991;**29**:364-369.

5. Schapira AHV, Cooper JM, Morgan-Hughes JA, *et al*. Mitochondrial myopathy with a defect of mitochondrial protein transport. *N Engl J Med* 1990;**323**:37-42.

J Neurol Neurosurg Psychiatry 1998;**64:**410-411 (March)

Copyright © 1998 by the BMJ Publishing Group Ltd.